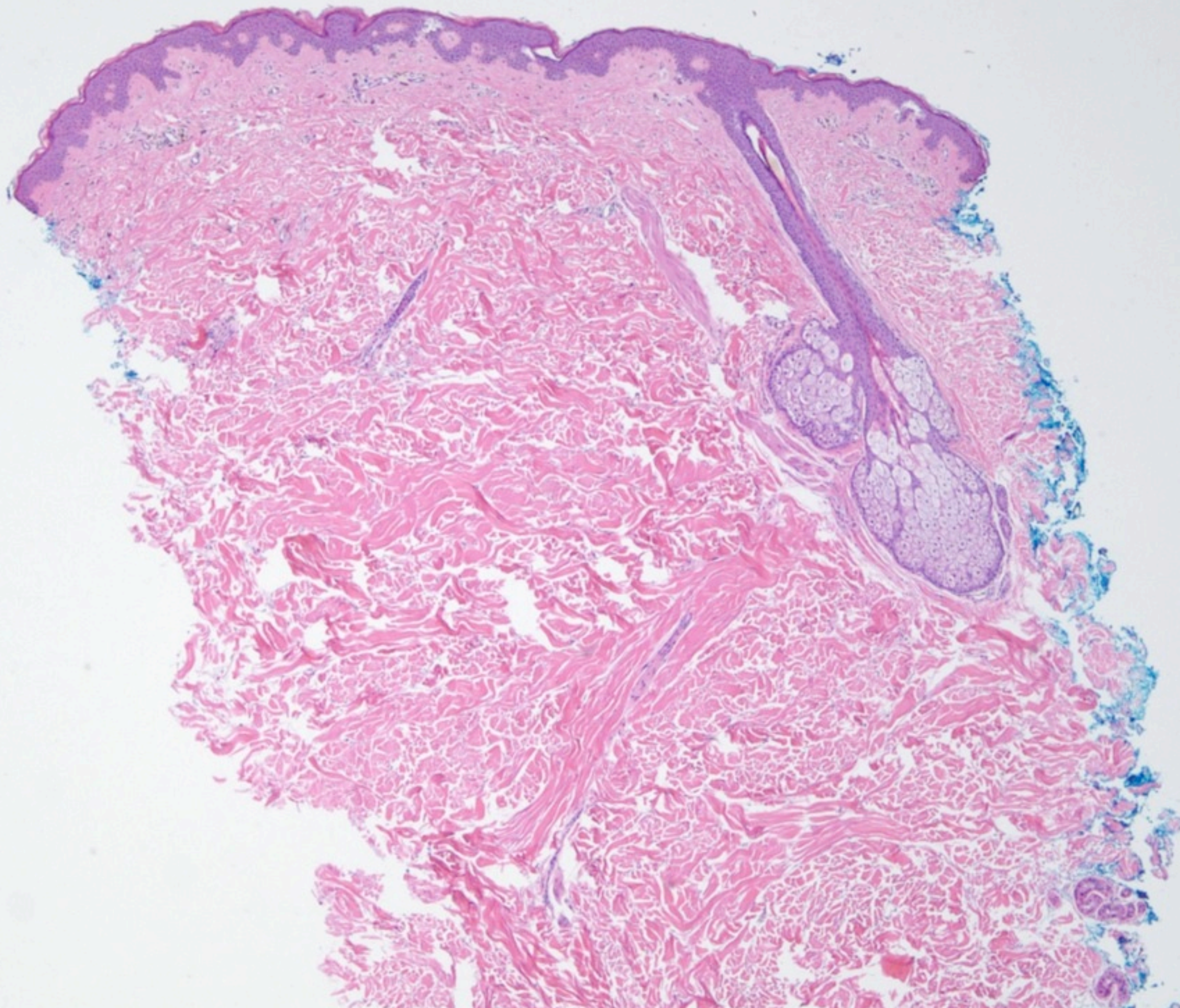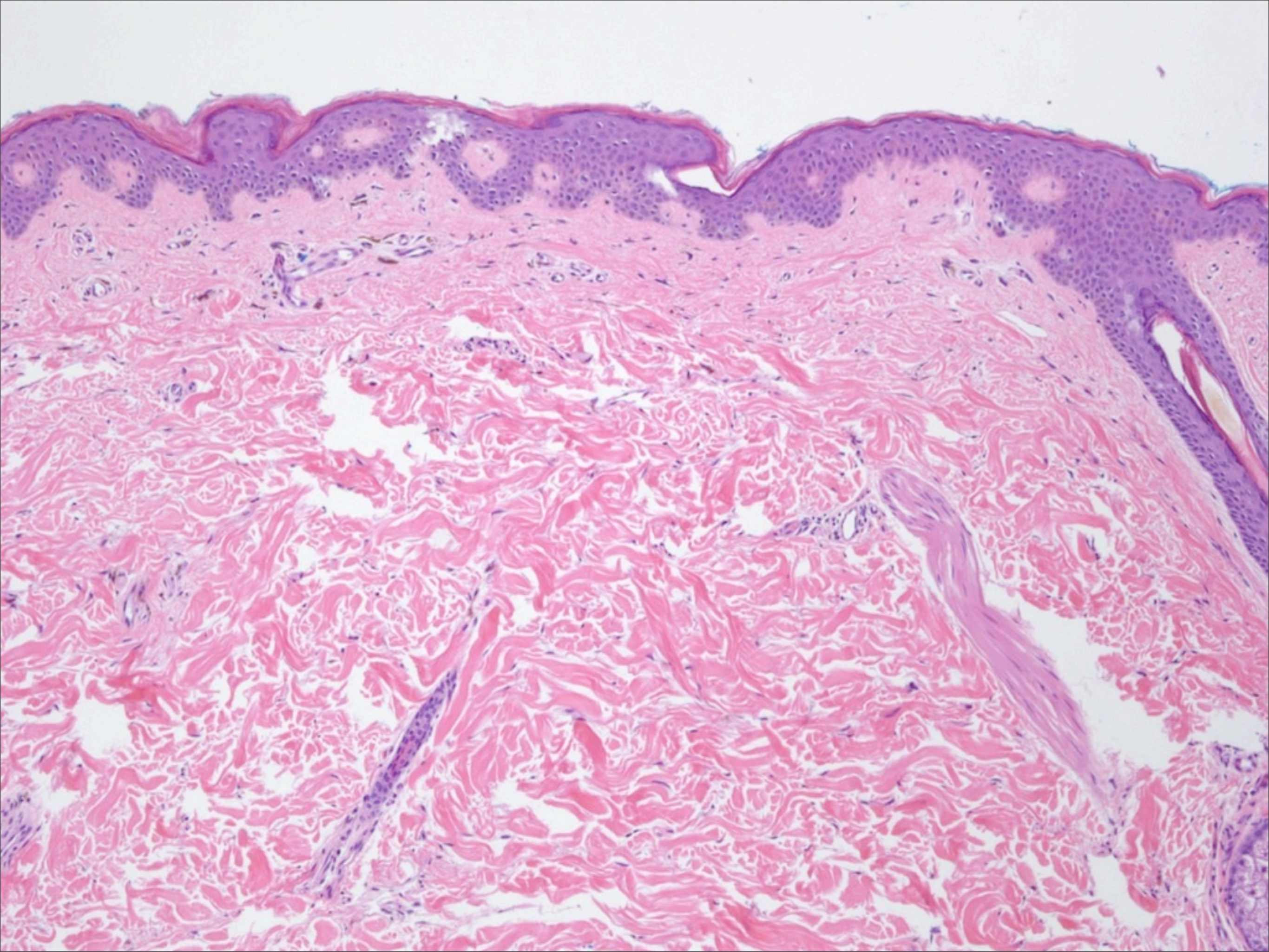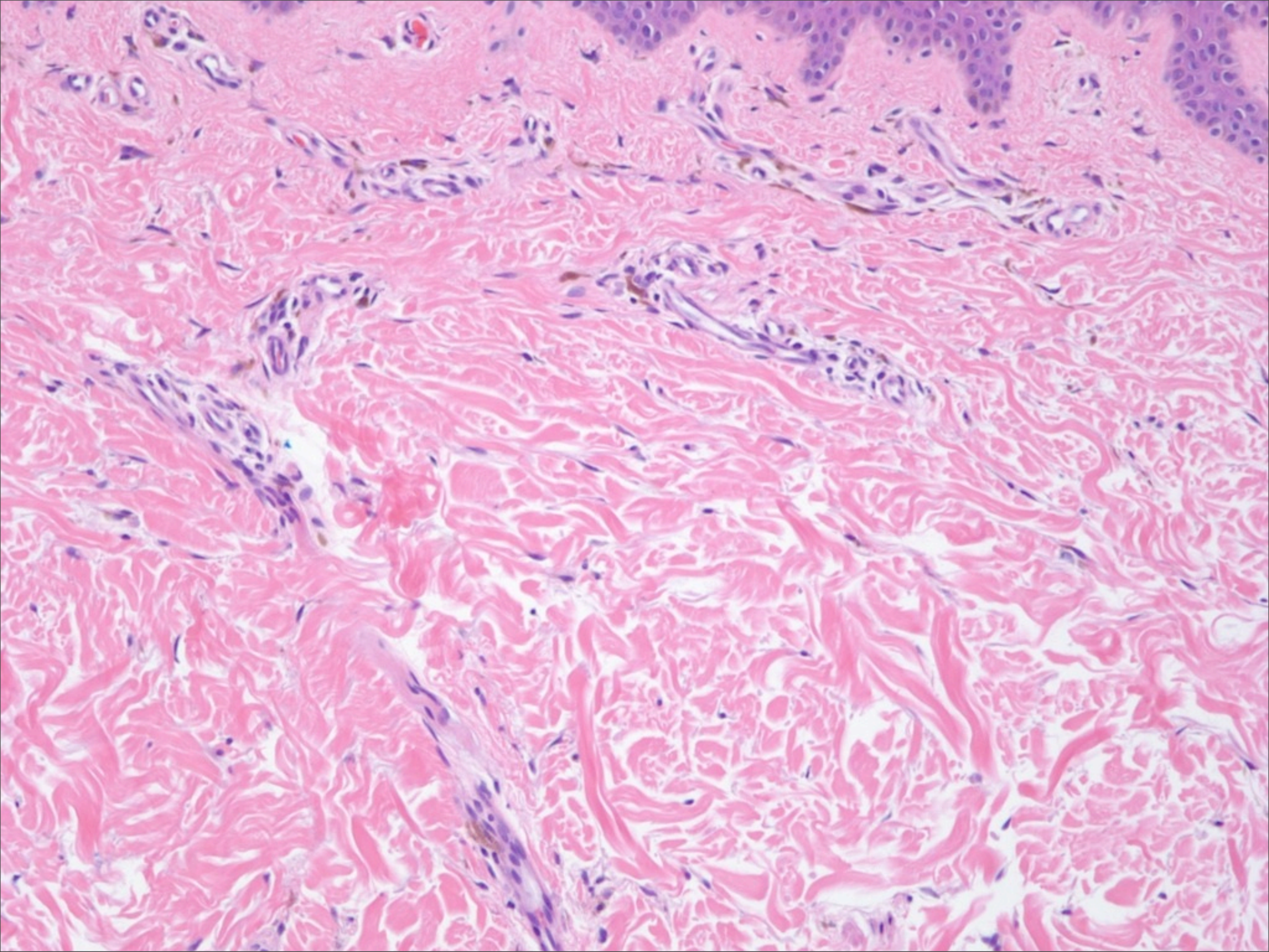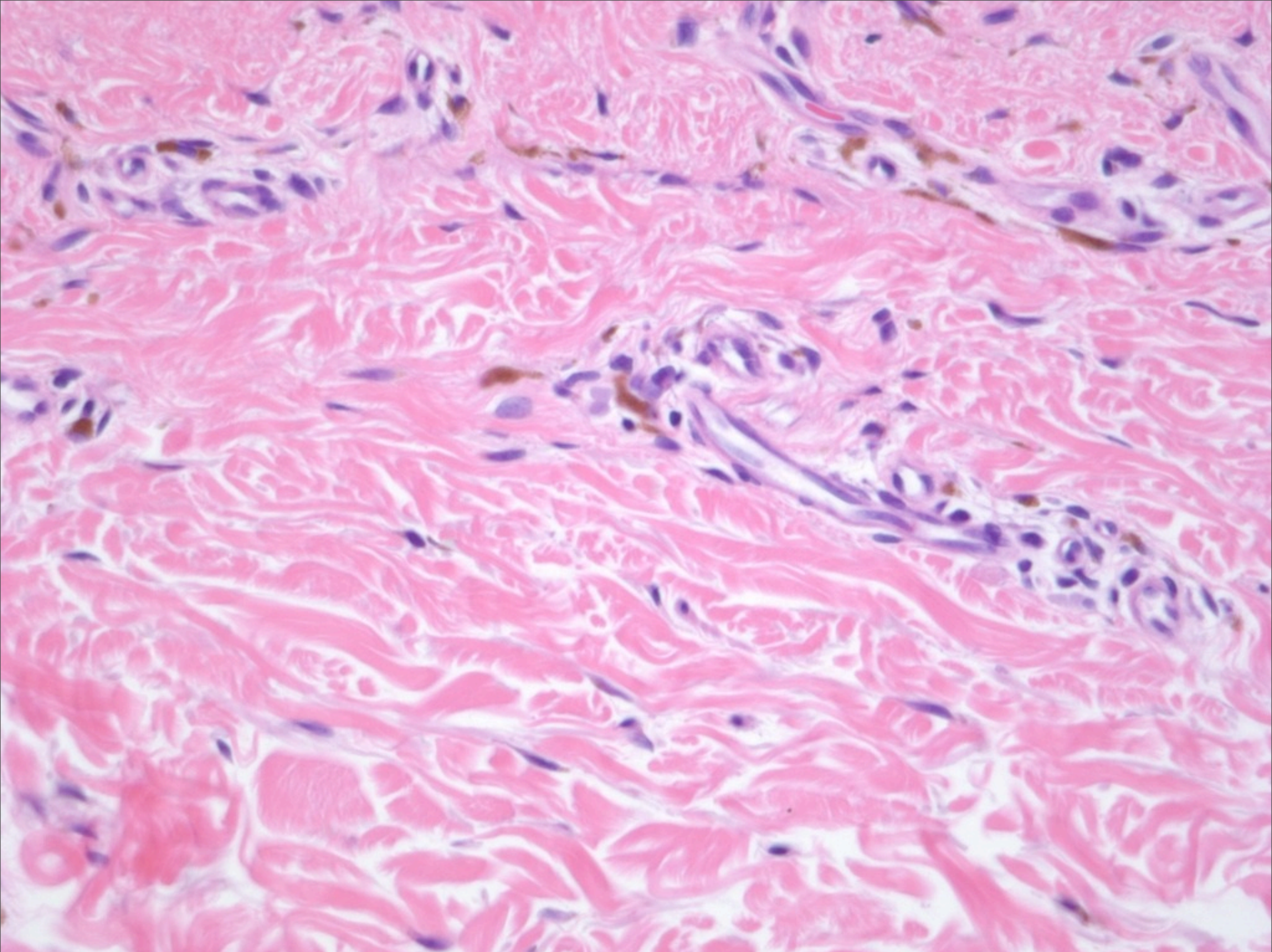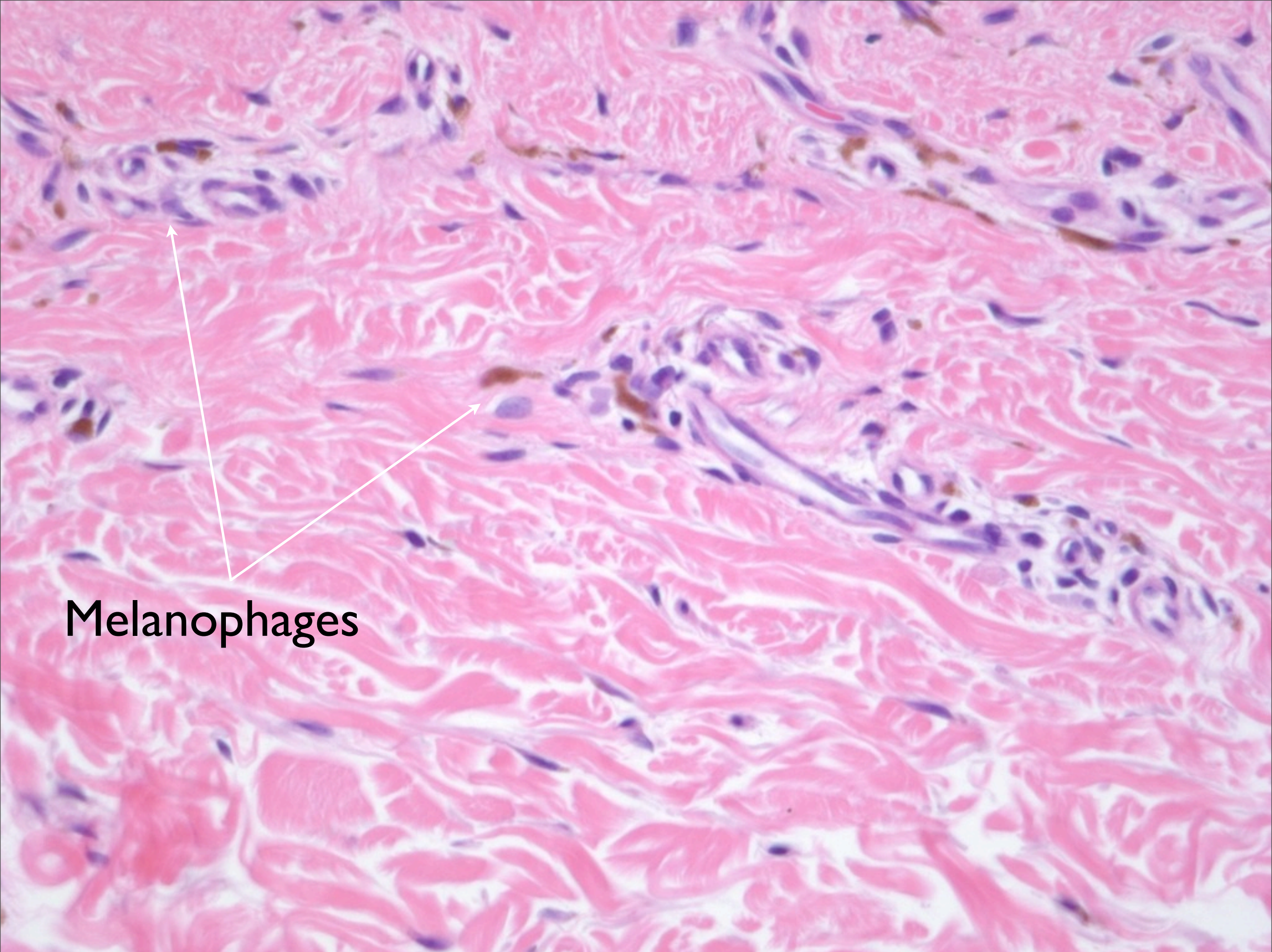


Changes Consistent with Notalgia Paresthetica

Notes

- Notalgia paresthetica is a clinical-pathologic correlation
- Biopsies show changes consistent with post-inflammatory pigmentary alteration with melanophages
- A Congo red stain may be helpful to rule out amyloidosis, which may sometimes co-exist



Melanophages